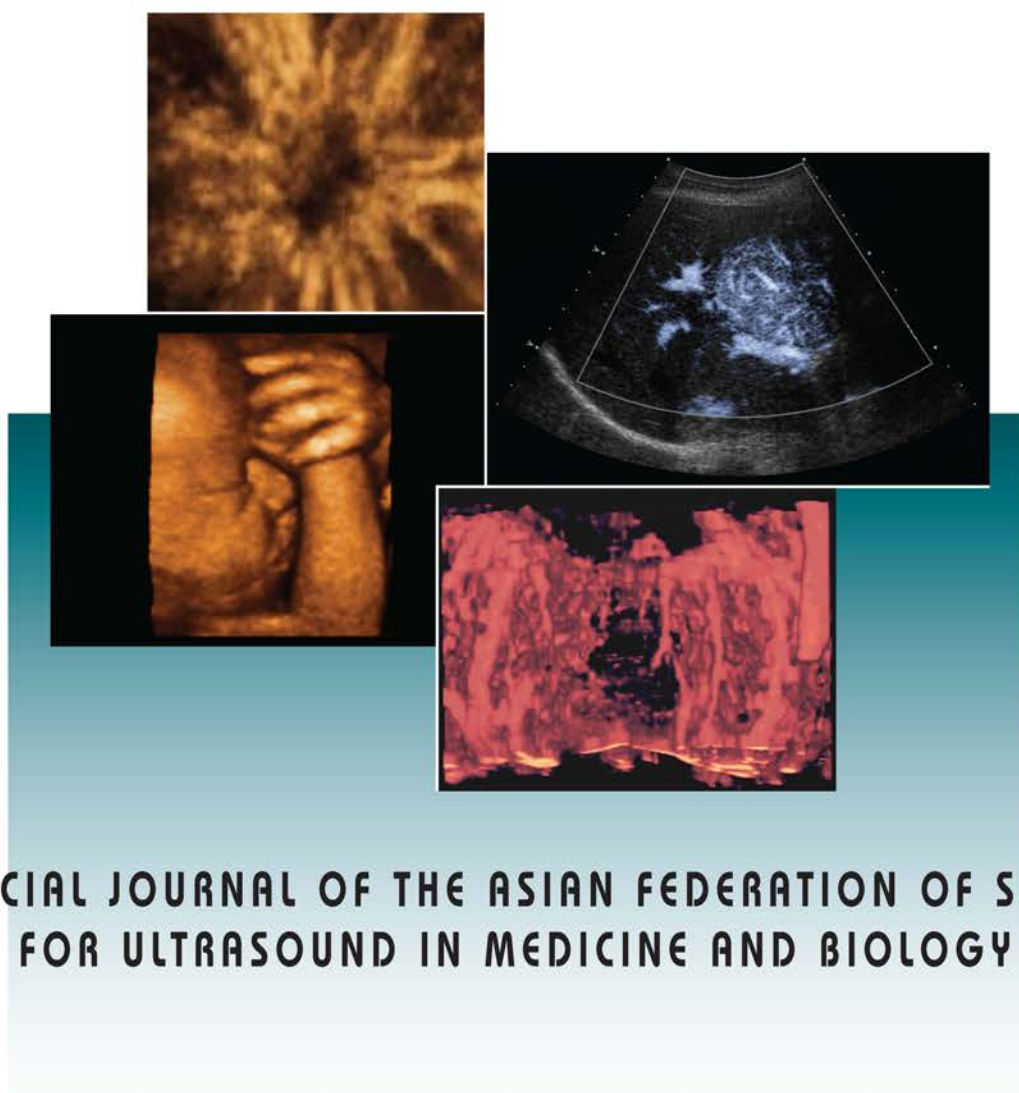
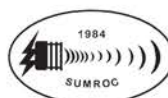
JOURNAL OF MEDICAL ULTRASOUND



THE OFFICIAL JOURNAL OF THE ASIAN FEDERATION OF SOCIETIES
FOR ULTRASOUND IN MEDICINE AND BIOLOGY



Inter-Rater and Intra-Rater Reliability of Sonographic Median Nerve and Wrist Measurements

Consuelo B. Gonzalez-Suarez^{1,2,3*}, Ma. Lorraine D. Buenavente², Ronald Christopher A. Cua², Maria Belinda C. Fidel^{2,4}, Jan-Tyrone C. Cabrera², Carina Fatima G. Regala²

¹Department of Physical Medicine and Rehabilitation, Faculty of Medicine and Surgery, University of Santo Tomas, ²Department of Physical Medicine and Rehabilitation, University of Santo Tomas Hospital, ⁴Center for Health Research and Movement Science, University of Santo Tomas, Manila, ³SPC Medical Center, San Pablo, Laguna, Philippines

Abstract

Background: Electrophysiologic studies have been considered the “gold standard” in diagnosing carpal tunnel syndrome (CTS); however, reports of false-negative results, as well as discomfort for the patient during the procedure has paved the use of ultrasound, being a painless and cost-efficient tool, as an alternative means for its diagnosis. Various ultrasound parameters assessing the median nerve and wrist dimensions have been described, but description of landmarks to assess these in a reliable manner has been lacking. **Methodology:** A systematic search of different databases yielded data regarding ultrasound parameters for CTS diagnosis, the landmarks used, and presence of reliability testing. Based on this, three sonologists discussed the external and sonographic landmarks that will be used in measuring the median nerve measurements, bowing of the flexor retinaculum and the carpal tunnel dimensions. A pilot test with two consecutive healthy participants using the discussed ultrasound parameters was carried out, and results were subjected to inter- and intra-rater reliability testing. Modifications were accordingly made on the acquisition of ultrasound image using external landmarks. The reliability testing proper was done with ten consecutive healthy participants. **Results:** Based on the systematic review and the pilot study, external landmarks were used to locate the median nerve in the forearm, carpal tunnel inlet and outlet. For the forearm measurement, it was taken 10 cm proximal from the distal palmar crease. The distal palmar crease was the external landmark used for the carpal tunnel inlet, while for the carpal tunnel outlet; it was measured 1 cm distal to the distal palmar crease. Instead of using the inner edge of the hook of hamate and trapezium, the apices of these bones were used as the landmarks in measuring the carpal tunnel outlet dimensions. There was excellent intra-rater reliability (mid-forearm, carpal tunnel inlet and outlet) except for the following: cross-sectional area (CSA) of the median nerve at the carpal tunnel inlet and outlet; and bowing of the flexor retinaculum. All the parameters had an excellent inter-rater reliability measured at the three levels (intraclass correlation [ICC]: Of 0.77–0.99) except for CSA of the median nerve at the levels of the forearm (fair-to-good with ICC of 0.71) and the carpal tunnel inlet (fair-to-good reliability of ICC: 0.43). **Conclusion:** There was an improved inter- and intra-rater reliability when external landmarks were used instead of sonographic landmarks.

Keywords: Carpal tunnel, median nerve, ultrasonographic measurements

INTRODUCTION

Carpal tunnel syndrome (CTS) is the most common entrapment neuropathy of the median nerve at the level of the wrist with a usual presentation of sensory deficit of the second and third digits and variably the thumb and lateral fourth digit.^[1] The diagnosis is based on its clinical presentation and electrophysiological studies. Electrophysiological studies have been considered the “gold standard” in its diagnosis; however, false-negative rates for nerve conduction studies have

been seen with a range of 16%–34%.^[2] Furthermore, it is also uncomfortable to the patients and does not give information on the anatomy of the median nerve and its surrounding structures. Recently, ultrasonography has emerged as a painless and cost-efficient diagnostic alternative to electrodiagnostic studies.^[3] Evidence-based guidelines of the American

Address for correspondence: Dr. Consuelo B. Gonzalez-Suarez, Faculty of Medicine and Surgery, University of Santo Tomas, Manila, Philippines 1008.
E-mail: bebet Suarez61@gmail.com

Received: 02-02-2017 Accepted: 14-04-2017 Available Online: 28-03-2018

Access this article online

Quick Response Code:



Website:
www.jmuonline.org

DOI:
10.4103/JMU.JMU_2_17

This is an open access journal, and articles are distributed under the terms of the Creative Commons Attribution-NonCommercial-ShareAlike 4.0 License, which allows others to remix, tweak, and build upon the work non-commercially, as long as appropriate credit is given and the new creations are licensed under the identical terms.

For reprints contact: reprints@medknow.com

How to cite this article: Gonzalez-Suarez CB, Buenavente LD, Cua RA, Fidel MC, Cabrera JTC, Regala CG. Inter-rater and intra-rater reliability of sonographic median nerve and wrist measurements. J Med Ultrasound 2018;26:14-23.

Association of Neuromuscular and Electrodiagnostic Medicine concluded that the median nerve cross-sectional area (CSA) at the wrist is the most accurate among the ultrasound parameters in diagnosing CTS. However, it stated that it would be useful to establish reference values and parameters in diagnosing CTS using ultrasound.^[4] It also recommended to assess the usefulness of other parameters used in the evaluation of CTS such as median nerve flattening, mobility, echogenicity, vascularity, bowing of the flexor retinaculum, and median nerve CSA ratio.^[4] Except for the CSA of median nerve at the carpal tunnel inlet, researchers studying the different sonographic parameters being employed in the CTS have not described succinctly the landmarks to be utilized for a reliable assessment, which could be one of the factors that account for the differences in the validity of these parameters in accurately diagnosing CTS.^[5-8]

Ultrasound also allows the visualization of the structures within the carpal tunnel and the bony borders of the tunnel. Studies have shown that wrist dimensions are risk factors in the development of CTS. The study of Kamolz *et al.* Moghtaderi and Vögelin *et al.* showed that a more quadratic wrist configuration was associated with CTS while that of Claes *et al.*, showed a significant correlation between the CSA of the median nerve at the wrist and wrist circumference.^[9-12] Only the study of Vögelin *et al.* used ultrasound to measure the internal carpal tunnel configuration while the other studies used external wrist measurement. However, the study was not able to describe concisely the landmarks used in measuring the carpal tunnel dimensions.^[11] Landmarks that are easily located improve the reliability and reproducibility of the sonographic measurements in the diagnosis of CTS. This is the preliminary study of the research project which seeks to determine the accuracy of various ultrasound parameters in diagnosing CTS. It reports on the appropriate landmarks that could be used in the measurement parameters of the median nerve used in the diagnosis of CTS and in assessing carpal tunnel dimensions. It also determines the inter- and intra-rater reliability of the measurement parameters using these landmarks.

METHODOLOGY

This study was approved by the Institutional Review Board of the University of Santo Tomas Hospital, Manila, Philippines. Informed consent was obtained from the participants. The study was composed of three phases: systematic review, the pilot study, and reliability testing proper done from December 2015 to May 2016.

Systematic review

A search of the databases to find studies using ultrasound in the diagnosis of CTS, with the key concepts of diagnostic accuracy, ultrasound or sonography, and carpal tunnel syndrome or CTS, was done. The databases included PubMed, EBSCO, BMJ, CINAHL, Science Direct, ProQuest, Scopus, and Google Scholar. The data extracted from these studies comprised of ultrasound parameters for CTS diagnosis, the

landmarks used, and presence of reliability testing, which were summarized in the table form.

Pilot study

Testers

Three sonologists were physiatrists who have been trained and have been performing musculoskeletal ultrasound for 7 years (BF and CS) and 3 years (TC), respectively.

Methods

The sonologists discussed the external and sonographic landmarks that will be used in measuring the median nerve measurements, bowing of the flexor retinaculum, and the carpal tunnel dimensions, which were based on the results of the systematic search. The median nerve dimensions consisting of anteroposterior diameter, transverse diameter, and CSA [Figure 1d] were measured at the level of the forearm, carpal tunnel inlet, and carpal tunnel outlet [Figure 1a-c].

Median nerve dimensions were measured at the forearm 10 cm proximal to the distal wrist crease. The median nerve was assessed at two levels for the carpal tunnel inlet, which were at the levels of the pisiform bone and the distal radioulnar joint. To locate the pisiform bone, the flexor carpi ulnaris tendon was initially identified in the transverse plane. Its tendon lies superficial to the pisiform bone where it is inserted.^[13] The distal radioulnar joint is considered as the proximal edge of the flexor retinaculum and the distal boundary of the pronator quadratus.^[13,14] The distal radius and ulna were identified. To further ensure that the median nerve image was taken at the distal radioulnar joint, pronator quadratus was also identified. Its muscle belly lies over the volar aspect of the distal metaphysis of the radius and ulna, and its fascicles are oriented transversely in contrast to the flexor digitorum superficialis and profundus, which were oriented longitudinally.^[13] The scanning proceeded from the mid-forearm up to the distal wrist crease to determine the point where the pronator quadratus was not already evident. At this point, the median nerve dimensions were measured.^[15]

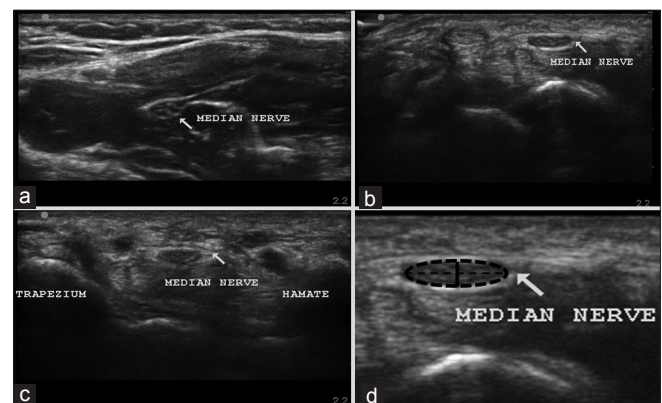


Figure 1: Median nerve measurements at the level of the (a) mid-forearm at 10 cm proximal of distal wrist crease; (b) carpal tunnel inlet at the level of the pisiform; (c) carpal tunnel outlet at the level of the hook of hamate; (d) Median nerve measurements: anteroposterior diameter (solid line); transverse diameter (dashed line); and cross-sectional area (dotted line)

The hook of hamate was the sonographic landmark for the carpal tunnel outlet. The inner edge of the hook of hamate and the trapezium was the sonographic landmark for assessing the palmar bowing of the flexor retinaculum. These bones were recognized by their shapes. The trapezium was identified with its flat palmar surface while the hook of hamate was identified by its small curvilinear profile located closer to the midline as compared to the pisiform.^[13]

The sonographic landmarks used for the palmar bowing of the flexor retinaculum were also used for assessing the radioulnar diameter while the apex of the flexor retinaculum and the lunate were the landmarks utilized measuring the dorsopalmar diameter of the carpal tunnel. The carpal tunnel dimensions were assessed at the level of the hook of hamate.

Two practice sessions were held before the pilot study to ensure that the sonologists were able to locate the sonographic landmarks used in the ultrasound protocol.

Musculoskeletal image acquisition

A SonoSite Edge II ultrasound (FUJIFILM SonoSite, Inc., Washington, USA) with a 38-mm linear array transducer with a frequency of 6–13 megahertz was used. The patient sat comfortably with the arm on the table in a position of flexed elbow, forearm supinated, wrist in neutral position, and fingers semiflexed.

The ultrasound probe was positioned perpendicular to the long axis of the forearm. The anteroposterior and transverse diameters; and CSA of the median nerve were measured in four locations namely at the forearm, the radioulnar joint and the levels of the pisiform and the hook of hamate using the agreed sonographic and external landmarks. The median nerve was visualized in longitudinal and transverse planes to confirm identification of the nerve. The widest anteroposterior and transverse diameters were measured. For the CSA measurement, the electronic ellipse function was used if the nerve had an elliptical shape. If the nerve was not elliptical, the continuous trace method was utilized. The margin of the median nerve was defined as the margin outside the hypoechoic nerve fascicles and inside the hyperechoic nerve sheath. Median nerves that were bifid were not included for the pilot study.

The wrist dimensions and bowing of the flexor retinaculum were measured at the level of the hook of hamate. Radioulnar and dorsopalmar diameters were determined by measuring the distance between the inner edge of the hook of hamate and the trapezium; and the apex of the flexor retinaculum and the lunate, respectively.

To minimize artificial nerve deformity due to differential loads, pressure to the hand was avoided during scanning and measurement. Both hands of the participants were assessed, and measurements were done three times and recorded.

Pilot testing

Pilot testing was done with two consecutive healthy participants (one male and female) with a mean age of

28.5 ± 0.70 . The participants were examined by the three sonologists within 1 week. The sonologists were blinded of the results obtained by the other sonologists. After the pilot testing, there was a discussion among the sonologists about the technical difficulties encountered during musculoskeletal imaging acquisition. The results of the statistical analysis were likewise reviewed.

Statistical analysis

All data were entered into a purposely-built MS Excel spreadsheet. IBM SPSS Statistics 21.0 (IBM Corp., Armonk, NY, USA) was used for statistical analysis. Means and standard deviation were used for the descriptive data. Kruskal–Wallis test or one way-ANOVA was used to determine if there was statistical difference in the measurements of the three sonologists. Intraclass correlation (ICC) was utilized to determine the inter- and intra-rater reliability. ICC values were interpreted as follows: >0.75 was excellent, 0.40 – 0.75 was fair-to-good, and <0.40 was poor.^[16]

Reliability testing proper

After the discussion and reviewing the results of the inter- and intra-rater reliability testing, appropriate changes were implemented on the manner of musculoskeletal image acquisition. Ultrasound image acquisition was performed on ten participants within 1 week using the revised ultrasound protocol.

Participants

Sample size calculation: A minimum sample size of twenty wrists from ten participants was needed to obtain a power of 0.80 and a significance level of 0.05 .

Ten consecutive healthy individuals composed of five males with a mean age of 27.4 ± 4.34 years old and five females with a mean age of 26.2 ± 3.42 years old were included in the study. They were excluded from the study if they have a history of neck or hand pain; history of any hand surgery; presence of cervical radiculopathy, peripheral neuropathy, or CTS; presence of systemic diseases such as diabetes mellitus, thyroid disease, connective tissue disease, or obesity that predispose to the development of CTS.

The statistical analysis used in the pilot testing was also utilized in the test proper.

RESULTS

Systematic review

Table 1 shows the different parameters for CTS diagnosis. It includes the following: flattening ratio using the anteroposterior and transverse diameters of the median nerve; CSA of the median nerve at the mid-forearm, carpal tunnel inlet, and carpal tunnel outlet; bowing of the flexor retinaculum; and the wrist forearm ratio by dividing the CSA of the median nerve at the forearm over the CSA of median nerve either at the carpal tunnel inlet or outlet. The wrist measurements are radioulnar and dorsopalmar diameters of the carpal tunnel.

Table 1: Results of the systematic review for the sonographic parameters used in the diagnosis of carpal tunnel syndrome and the landmarks used

Carpal tunnel inlet		
Landmarks used	Authors	Interrater reliability
A. Median nerve: CSA; flattening ratio (anteroposterior diameter/transverse diameter) and wrist forearm ratio (CSA of the median nerve at the level of mid forearm/CSA of the median nerve at the level of the carpal tunnel inlet or carpal tunnel outlet)		
Pisiform	Altinok <i>et al.</i> , 2004 ^[17] Bayrak <i>et al.</i> , 2007 ^[18] Buchberger <i>et al.</i> , 1992 ^[19] Fowler <i>et al.</i> , 2014 ^[20] Ghasemi-Esfe <i>et al.</i> , 2011 ^[21] Ghasemi-Esfe <i>et al.</i> , 2011 ^[22] Kaymak <i>et al.</i> , 2008 ^[6] Keles <i>et al.</i> , 2005 ^[23] Kim <i>et al.</i> , 2014 ^[14] Kotevoglul and Gülbahce-Saglam, 2005 ^[7] Kwon <i>et al.</i> , 2008 ^[24] Lee <i>et al.</i> , 2005 ^[25] Yesildag <i>et al.</i> , 2004 ^[25] Zhang <i>et al.</i> , 2015 ^[27]	Ghasemi-Esfe <i>et al.</i> , 2011: ^[21] Inter-correlation $\kappa=0.761$, $P<0.001$ with hypervascularity and/or high CSA of median nerve with electrodiagnostic test
Pisiform and scaphoid	El Miedany <i>et al.</i> , 2015 ^[28] Mohammadi <i>et al.</i> , 2010 ^[8] Mohammadi <i>et al.</i> , 2012 ^[29] Naranjo <i>et al.</i> , 2007 ^[30] Paliwal <i>et al.</i> , 2014 ^[5]	El Miedany <i>et al.</i> , 2015: ^[28] Interrater reliability - ICC of median nerve CSA: 0.90 (95% CI 0.79-0.95), flattening ratio: 0.85 (95% CI 0.8-0.9)
External: Distal wrist crease Sonographic landmark: Pisiform	Claes <i>et al.</i> , 2010 ^[12] Claes <i>et al.</i> , 2013 ^[31] El Miedany <i>et al.</i> , 2004 ^[32] Mhoon <i>et al.</i> , 2012 ^[3] Wiesler <i>et al.</i> , 2006 ^[33]	Mhoon <i>et al.</i> , 2012: ^[3] Interrater reliability - median nerve CSA: $r=0.98$, wrist forearm ratio: $r=0.96$
Radio ulnar joint	Altinok <i>et al.</i> , 2004 ^[17] Bayrak <i>et al.</i> , 2007 ^[18] Buchberger <i>et al.</i> , 1992 ^[19] Kaymak <i>et al.</i> , 2008 ^[6] Keles <i>et al.</i> , 2005 ^[23] Kotevoglul and Gülbahce-Saglam, 2005 ^[7] Lee <i>et al.</i> , 2005 ^[25]	None
Carpal tunnel outlet Hook of hamate	Altinok <i>et al.</i> , 2004 ^[17] Buchberger <i>et al.</i> , 1992 ^[19] Keles <i>et al.</i> , 2005 ^[23] Kotevoglul and Gülbahce-Saglam, 2005 ^[7] Kwon <i>et al.</i> , 2008 ^[24] Lee <i>et al.</i> , 2005 ^[25] Zhang <i>et al.</i> , 2015 ^[27]	None
Hook of hamate and trapezium	Mohammadi <i>et al.</i> , 2010 ^[8] Naranjo <i>et al.</i> , 2007 ^[30] Paliwal <i>et al.</i> , 2014 ^[5]	None
Forearm 12 cm proximal to wrist crease	Mhoon <i>et al.</i> , 2012 ^[3] Paliwal <i>et al.</i> , 2014 ^[5] Kang <i>et al.</i> , 2012 ^[34]	Mhoon <i>et al.</i> , 2012: ^[3] Interrater reliability - median nerve CSA: $r=0.98$, wrist forearm ratio: $r=0.96$
10 cm proximal to wrist crease	Zhang <i>et al.</i> , 2015 ^[27] Ghasemi-Esfe <i>et al.</i> , 2011 ^[21] Ghasemi-Esfe <i>et al.</i> , 2011 ^[22]	None

Contd...

Table 1: Contd...

Carpal tunnel inlet		
Landmarks used	Authors	Interrater reliability
B. Bowing of flexor retinaculum		
Trapezium and hook of hamate	Altinok <i>et al.</i> , 2004 ^[17] Bayrak <i>et al.</i> , 2007 ^[18] Buchberger <i>et al.</i> , 1992 ^[19] Keles <i>et al.</i> , 2005 ^[23] Kim <i>et al.</i> , 2014 ^[14] Kotevoglou and Gülbahce-Saglam, 2005 ^[7] Lee <i>et al.</i> , 2005 ^[25] Mohammadi <i>et al.</i> , 2012 ^[29] Naranjo <i>et al.</i> , 2007 ^[30]	None
C. Wrist dimensions		
Radioulnar distance: Trapezium and hook of hamate	Vögelin <i>et al.</i> , 2014 ^[11]	None
Dorsopalmar distance: Apex of flexor retinaculum to lunate	Vögelin <i>et al.</i> , 2014 ^[11]	None

CSA: Cross sectional area, CI: Confidence interval, ICC: Intraclass correlation

The landmark for the mid-forearm was the distal wrist crease, and the median nerve image was scanned 10 cm and 12 cm from the distal wrist crease. There were two areas where the median nerve was scanned at the carpal tunnel inlet which were at the level of the pisiform and distal radioulnar joint. There were three landmarks identified at the level of the pisiform which includes the following: pisiform; pisiform, and scaphoid; and distal wrist crease as the external marker and pisiform as the sonographic landmark. The sonographic landmark of the median nerve at the level of the radioulnar joint was the distal radioulnar joint. There were two methods of identifying the carpal tunnel outlet, one which used the hook of hamate and another using both the hook of hamate and the trapezium as landmarks.

Palmar bowing of the flexor retinaculum, which is the displacement (measured in millimeters) of the retinaculum, was measured as the distance from the palmar apex of retinaculum to a straight line drawn between the tubercle of trapezium and hook of hamate bone [Figure 2].^[18,23] For this, the landmarks used were the trapezium and hook of hamate. These were also the same landmarks used for the radioulnar distance while the apex of the flexor retinaculum and the lunate were the sonographic markers for the dorsopalmar distance.

Except for the studies of Ghasemi-Esfe *et al.* 2011a, Mhoon *et al.* 2012 and El Miedany *et al.* 2015, all the other studies had no reliability testing done on the methods of measuring of the ultrasound parameters used in the diagnosis of the CTS.^[3,21,28]

Pilot study

The results of the measurements of the three sonologists are tabulated in Table 2. There was statistical difference on the measurements of the three sonologists in all the levels except at the level of the forearm. The intra- and inter-tester reliability testing results are shown in Table 3.

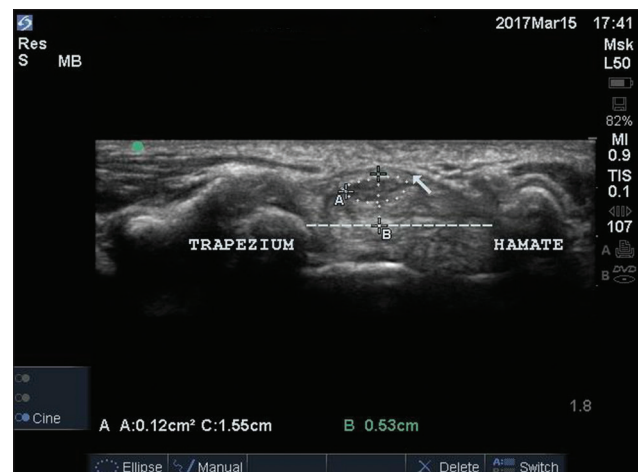


Figure 2: Palmar bowing of the flexor of the retinaculum (solid line) measured by the distance from the palmar apex of retinaculum to a (dashed line) drawn between the tubercle of trapezium and hook of hamate bone. Arrow- flexor of the retinaculum

It showed that the ultrasound image acquisition at the level of the forearm where an external landmark was used had an excellent inter- and intra-rater reliability. Median nerve measurements had excellent intra-rater reliability except for the anteroposterior diameter measurement of sonologists at the level of the pisiform. Inter-rater reliability at the level of the pisiform was fair to good. Measurements taken at the hook of hamate had fair-to-good and excellent intra-rater reliability of the three sonologists. However, inter-rater reliability had poor and fair-to-good results.

Results at the level of the radioulnar joint had the poorest outcome. The median nerve measurements at the level of the radioulnar joint had excellent and fair-to-good reliability. However, there was poor-to-problematic inter-rater reliability.

Table 2: Means and Standard Deviation of the wrist and median nerve measurements at the different landmarks

Dimensions measured (cm)	Sonologist 1	Sonologist 2	Sonologist 3	P
Median nerve at the forearm measurement (mean±SD)				
Anteroposterior diameter (cm)	0.18±0.06	0.18±0.04	0.18±0.04	0.969@
Transverse diameter (cm)	0.31±0.06	0.37±0.07	0.35±0.07	0.101@
Cross-sectional area (cm ²)	0.04±0.02	0.05±0.02	0.05±0.03	0.381@
Median nerve at the carpal tunnel inlet (level of pisiform) (mean±SD)				
Anteroposterior diameter (cm)	0.20±0.03	0.17±0.02	0.20±0.03	0.015*
Transverse diameter (cm)	0.42±0.05	0.53±0.09	0.47±0.05	0.002*
Cross-sectional area (cm ²)	0.06±0.01	0.07±0.14	0.08±0.02	0.003*
Median nerve at the carpal tunnel inlet (level of Radioulnar joint) (mean±SD)				
Anteroposterior diameter (cm)	0.17±0.03	0.15±0.04	0.20±0.01	0.001*
Transverse diameter (cm)	0.46±0.06	0.49±0.05	0.44±0.03	0.046*
Cross-sectional area (cm ²)	0.06±0.01	0.06±0.01	0.06±0.01	0.062@
Median nerve at the carpal tunnel outlet (level of the hook of hamate) (mean±SD)				
Anteroposterior diameter (cm)	0.20±0.02	0.18±0.02	0.20±0.02	0.014*
Transverse diameter (cm)	0.43±0.04	0.52±0.09	0.48±0.04	0.005*
Cross sectional area (cm ²)	0.06±0.01	0.07±0.02	0.07±0.02	0.059@
Other measurements performed at the level of the hook of hamate (mean±SD)				
Carpal outlet radioulnar distance (cm)	2.63±0.14	2.46±0.34	2.92±0.21	0.001*
Carpal outlet dorsopalmar distance (cm)	1.05±0.11	1.22±0.15	1.17±0.14	0.001*
Bowing of flexor retinaculum (cm)	0.28±0.06	0.36±0.15	0.25±0.08	0.042*

*Significant. SD: Standard deviation, cm: centimeter, @: non significant

Table 3: Summary of the reliability results of the wrist and median nerve measurements at the different landmarks

Dimensions measured (cm)	ICC (95% CI)			
	Intrarater reliability ^a			Interrater reliability ^a
	Sonologist 1	Sonologist 2	Sonologist 3	
Median nerve at the level of forearm				
Anteroposterior diameter (cm)	0.96 (0.74-0.99)	0.98 (0.85-0.99)	0.92 (0.45-0.99)	0.94 (0.85-0.98)
Transverse diameter (cm)	0.93 (0.56-0.99)	0.97 (0.82-0.99)	0.90 (0.32-0.99)	0.84 (0.47-0.95)
Cross-sectional area (cm ²)	0.84 (0.06-0.98)	0.96 (0.72-0.99)	0.95 (0.64-0.99)	0.89 (0.71-0.97)
Median nerve at the carpal tunnel inlet (level of pisiform)				
Anteroposterior diameter (cm)	0.93 (0.53-0.99)	0.87 (0.14-0.99)	0.26 (0.33-0.91)	0.67 (-2.19-0.04)
Transverse diameter (cm)	0.92 (0.47-0.99)	0.87 (0.79-0.80)	0.95 (0.69-0.99)	0.58 (0.02-0.86)
Cross-sectional area (cm ²)	0.84 (0.07-0.98)	0.93 (0.56-0.99)	0.99 (0.92-0.99)	0.57 (0.01-0.85)
Median nerve at the carpal tunnel inlet (level of radioulnar joint)				
Anteroposterior diameter (cm)	0.65 (0.29-0.97)	0.69 (0.07-0.97)	0.83 (0.28-0.99)	-1.06 (-1.76-0.29)
Transverse diameter (cm)	0.94 (0.58-0.99)	0.91 (0.39-0.99)	0.96 (0.75-0.99)	-1.37 (-4.42-0.21)
Cross-sectional area (cm ²)	0.69 (0.30-0.98)	0.82 (0.18-0.99)	0.61 (0.57-0.97)	0.31 (0.48-0.77)
Median nerve at the carpal tunnel outlet (level of the hook of hamate)				
Anteroposterior diameter (cm)	0.57 (0.12-0.97)	0.95 (0.67-0.99)	0.58 (0.18-0.97)	0.45 (0.14-0.80)
Transverse diameter (cm)	0.81 (0.23-0.99)	0.93 (0.51-0.99)	0.92 (0.47-0.99)	0.61 (0.04-0.87)
Cross sectional area (cm ²)	0.93 (0.51-0.99)	0.92 (0.47-0.99)	0.94 (0.57-0.9)	0.75 (0.32-0.92)
Other measurements performed at the carpal tunnel outlet (level of the hook of hamate)				
Carpal outlet radioulnar distance (cm)	0.89 (0.27-0.99)	0.74 (0.71-0.98)	0.80 (0.30-0.99)	0.18 (.05-0.72)
Carpal outlet dorsopalmar distance (cm)	0.63 (0.10-0.97)	0.71 (0.18-0.98)	0.90 (0.42-0.99)	0.74 (0.34-0.92)
Bowing of flexor retinaculum (cm)	0.92 (0.46-0.99)	0.98 (0.87-0.99)	0.51 (0.20-0.97)	0.13 (0.123-0.60)

^aICC values were interpreted as follows: >0.75 was excellent, 0.40-0.75 was fair to good and <0.40 was poor. ICC: Intraclass correlation, CI: Confidence interval

The discussion among the sonologists disclosed the following technical difficulties encountered during ultrasound acquisition which were the following: locating the distal end of the radioulnar joint using the pronator quadratus as the sonographic

landmark; differentiating the pisiform and hook of hamate; and locating the inner borders of the hook of hamate and trapezium. They concurred that the area where the median nerve is easily located and measured was at the level of the forearm.

Due to the results of the statistical analysis and discussion among the sonologists, the following changes were instituted during musculoskeletal image acquisition: external landmarks were provided for the pisiform and hook of hamate, which were the distal wrist crease and 1 cm distal to the distal wrist crease, respectively, the carpal tunnel inlet was measured at the level of the pisiform; the wrist radioulnar distance was measured using the apex of the hook of hamate and trapezium instead of its inner border, and bowing of the flexor retinaculum measured from the palmar apex to the line between the apex of the hook of hamate and trapezium. These landmarks were also used in the determination of bowing of the flexor retinaculum.

Reliability testing proper

Table 4 shows the mean and standards deviations of the measurements of all of parameters of the three sonologists. There was no statistical difference of all the measurements at the three levels among the three sonologists.

There was an excellent intra-rater reliability except for the for the following: CSA of the median nerve at the level of the pisiform and the hook of hamate; and bowing of the flexor retinaculum for Sonologist 3 which was fair to good. All the parameters had an excellent inter-rater reliability measured at the three levels except for CSA of the median nerve at the levels of the forearm and pisiform which had fair-to-good reliability [Table 5].

DISCUSSION

The study determined the most appropriate landmarks used to measure the median nerve at different levels and the wrist dimensions. We were also able to demonstrate that with these landmarks, median nerve and wrist dimension measurements produced excellent inter-rater reliability and good-to-excellent intra-rater reliability results.

In the assessment of CTS using ultrasound, one of the important factors is identifying landmarks with the highest diagnostic accuracy and reliability. To ensure this, most studies have chosen to standardize the level by having a reference to anatomical landmarks, which were either the distal radioulnar joint, the pisiform or the hook of hamate.^[5-7,17-23,24-27] These landmarks were identified by ultrasound. However, one of the limitations of musculoskeletal ultrasound is it is highly operator dependent which could affect the accuracy and reliability of identifying these sonographic landmarks. This was observed in our pilot study where there was variable agreement among the sonologists except for the measurements done in the level of the forearm where a surface landmark was used. With this, the researchers decided that external surface landmarks would improve the inter-rater reliability.

In assessing the median nerve at the carpal tunnel inlet, the pisiform was selected to be the sonographic landmark based on the systematic search where most of the studies used it as the marker.^[6,7,17-23,24-27] However, our study showed that using the distal wrist crease, which corresponds to the anatomic position of the pisiform as the external marker improved the inter-rater reliability to excellent results from a fair-to-good results. The wrist crease had been used by some studies as the landmark, but studies were far less as compared to those using the pisiform.^[3,12,31-33] However, all the studies had only one sonographer performing to the ultrasound to prevent variability of measurement. All of the studies except to that of El Miedany *et al.*, in the systematic search of studies done before the pilot study did not perform an inter-tester reliability assessment.^[28] The study of El Miedany showed that interrater reliability of the CSA of the median nerve was ICC: 0.90 (95% CI 0.79–0.95 at the level of the pisiform.^[28] However, he did not mention the landmarks used in assessing the median nerve at the carpal tunnel inlet.

Table 4: Means and Standard Deviation of the wrist and median nerve measurements using external landmarks

Dimensions measured (cm)	Sonologist 1	Sonologist 2	Sonologist 3	P ^a
Median nerve at the forearm measurement (mean±SD)				
Anteroposterior diameter (cm)	0.18±0.02	0.16±0.02	0.18±0.03	0.060 [@]
Transverse diameter (cm)	0.35±0.04	0.34±0.04	0.35±0.04	0.651 [@]
Cross-sectional area (cm ²)	0.05±0.01	0.04±0.01	0.05±0.01	0.062 [@]
Median nerve at the carpal tunnel inlet (mean±SD)				
Anteroposterior diameter (cm)	0.17±0.02	0.16±0.03	0.17±0.02	0.372 [@]
Transverse diameter (cm)	0.51±0.09	0.55±0.09	0.51±0.08	0.071 [@]
Cross-sectional area (cm ²)	0.07±0.06	0.06±0.02	0.06±0.02	0.062 [@]
Median nerve at the carpal tunnel outlet (mean±SD)				
Anteroposterior diameter (cm)	0.17±0.03	0.17±0.03	0.18±0.03	0.071 [@]
Transverse diameter (cm)	0.52±0.10	0.53±0.11	0.50±0.11	0.183 [@]
Cross sectional area (cm ²)	0.07±0.01	0.07±0.01	0.07±0.01	0.064 [@]
Other measurements performed at the carpal tunnel outlet (mean±SD)				
Carpal outlet radioulnar distance (cm)	2.97±0.34	2.96±0.34	2.98±0.36	0.971 [@]
Carpal outlet dorsopalmar distance (cm)	1.07±0.10	1.04±0.09	1.06±0.10	0.262 [@]
Bowing of the flexor retinaculum (cm)	0.14±0.18	0.13±0.06	0.16±0.08	0.060 [@]

^aComputed using one-way ANOVA or Kruskal-Wallis test, Significantly different. cm: Centimeter; SD: Standard deviation; a: Computed using one-way ANOVA or Kruskal-Wallis test; @: No statistical difference

Table 5: Summary of the reliability results of the wrist and median nerve measurements using external landmarks

Dimensions measured (cm)	ICC (95% CI)			
	Intrarater reliability ^a			Interrater reliability ^a
	Rater 1	Rater 2	Rater 3	
Median nerve at the level of the forearm				
Anteroposterior diameter (cm)	0.81 (0.60-0.92)	0.85 (0.68-0.93)	0.89 (0.77-0.95)	0.84 (0.66-0.93)
Transverse diameter (cm)	0.81 (0.59-0.92)	0.90 (0.79-0.96)	0.78 (0.54-0.91)	0.86 (0.70-0.94)
Cross sectional area (cm ²)	0.87 (0.72-0.94)	0.92 (0.83-0.97)	0.87 (0.73-0.95)	0.71 (0.38-0.87)
Median nerve at the carpal tunnel inlet				
Anteroposterior diameter (cm)	0.87 (0.73-0.95)	0.94 (0.87-0.98)	0.81 (0.60-0.92)	0.84 (0.66-0.93)
Transverse diameter (cm)	0.97 (0.93-0.99)	0.94 (0.88-0.98)	0.97 (0.93-0.99)	0.96 (0.91-0.98)
Cross sectional area (cm ²)	0.76 (0.34-0.86)	0.85 (0.67-0.93)	0.71 (0.38-0.87)	0.43 (0.19-0.76)
Median nerve at the carpal tunnel outlet				
Anteroposterior diameter (cm)	0.96 (0.91-0.98)	0.94 (0.88-0.98)	0.93 (0.85-0.97)	0.83 (0.63-0.93)
Transverse diameter (cm)	0.95 (0.89-0.98)	0.98 (0.97-0.99)	0.95 (0.88-0.98)	0.97 (0.94-0.99)
Cross sectional area (cm ²)	0.89 (0.76-0.95)	0.75 (0.48-0.90)	0.69 (0.34-0.87)	0.77 (0.52-0.90)
Other measurements performed at the carpal tunnel outlet				
Carpal outlet radioulnar distance (cm)	0.81 (0.59-0.92)	0.94 (0.86-0.97)	0.83 (0.64-0.93)	0.99 (0.98-0.99)
Carpal outlet dorsopalmar distance (cm)	0.98 (0.96-0.99)	0.99 (0.98-0.99)	0.86 (0.72-0.94)	0.84 (0.67-0.93)
Bowing of the flexor retinaculum (cm)	0.93 (0.86-0.97)	0.92 (0.84-0.97)	0.58 (0.25-0.68)	0.88 (0.75-0.95)

^aICC (Fleiss 1986) values were interpreted as follows: >0.75 was excellent, 0.40-0.75 was fair-to-good and <0.40 was poor. ICC: Intraclass correlation, CI: Confidence interval

The distal radioulnar joint as the landmark for the carpal tunnel obtained the most unreliable results. This may be due to the fact that the pronator quadratus was used as the sonographic landmark to demarcate the joint. The pronator quadratus muscle is comprised of the deep and superficial layers. It is attached to the anterior aspects of the distal sixth of the radius and ulna and the distal radioulnar joint, which makes it suitable as one of the sonographic markers of distal radioulnar joint.^[35] This technique was similar to the study of Klauser *et al.*, where the median nerve is measured in the area where the pronator quadratus was not visible already.^[15] However, the judgment of the sonologist, transducer placement, and presence of anisotropy could have affected the ultrasound image of the muscle providing a not too accurate sonographic landmark. This was substantiated during the discussion among the sonologists. This led the researchers to choose the level of the pisiform as the better level to determine median nerve dimensions at the carpal tunnel inlet.

In assessing the median nerve at the carpal tunnel outlet, the landmark used in the pilot study was the hook of hamate based on the systematic search. However, this sonographic landmark showed a variable inter- and intra-tester reliability. Changing the sonographic landmark to a surface landmark of 1 cm distal to the distal wrist crease, which corresponds to the location of the hook of hamate improved the inter- and intra-rater reliability to excellent.^[36,37] A study by Fu *et al.*, (2015) showed that the inter-rater reliability and intra-rater reliability using the hook of hamate as the landmark was 0.79 and 0.85 for the carpal tunnel outlet CSA.^[38] This may be due to the fact that only one sonologist with a 10-year experience in musculoskeletal ultrasound performed the sonographic imaging of the participants of the study.

The issues that the sonologists faced in assessing the bowing of the flexor retinaculum was the landmark for locating the hook of hamate and the point on the trapezium and hook of hamate which will be connected to draw a line. Initially, the sonographic landmark of the hook of hamate was used; and the inner border of the hook of hamate and trapezium were used as points that will be connected to draw a line. The pilot study showed poor-to-good inter-rater reliability. Locating the inner border of the bones proved to be difficult because of pitfalls in performing bony sonography such as incorrect position of transducer, heterogeneity by geometric relationship of the bone and anisotropy.^[39]

Furthermore, if the probe cannot be positioned perpendicular to the area of interest such as the inner border of the trapezium and hamate, the sound waves cannot be reflected back to the transducer, the border of the bones would not be visualize clearly. In our study, this is illustrated by the poor inter- and intra-tester reliability when the inner border of the bones was used as landmarks. However, when the landmark was the apex of the bones, which was more superficial as compared to the inner border of the bone, and the transducer had better access, the reliability improved markedly.^[40]

CONCLUSION

There was an improved inter-rater reliability when external landmarks were used instead of sonographic landmarks. This study could provide the impetus in order that future studies would utilize these landmarks for a better reproducibility of results.

Limitations

The authors did not perform quality appraisal for diagnostic the accuracy of the papers included in the systematic search nor

did they perform a meta-analysis for diagnostic accuracy for the results of the paper. This is because the primary objective for the systematic search was to determine what were the landmarks used by the papers in assessing the measurement of the median nerve at the different levels. The search has shown that there were varying landmarks used by the authors, which could be the probable reason for the inconsistent results of the paper. Furthermore, there were only two participants for the pilot study. However, the discussion among the sonologists after the pilot study affirmed the results of the pilot study.

Financial support and sponsorship

Nil.

Conflicts of interest

There are no conflicts of interest.

REFERENCES

1. Ibrahim I, Khan WS, Goddard N, Smitham P. Carpal tunnel syndrome: A review of the recent literature. *Open Orthop J* 2012;6:69-76.
2. Witt JC, Hentz JG, Stevens JC. Carpal tunnel syndrome with normal nerve conduction studies. *Muscle Nerve* 2004;29:515-22.
3. Mhoon JT, Juel VC, Hobson-Webb LD. Median nerve ultrasound as a screening tool in carpal tunnel syndrome: Correlation of cross-sectional area measures with electrodiagnostic abnormality. *Muscle Nerve* 2012;46:871-8.
4. Cartwright MS, Hobson-Webb LD, Boon AJ, Alter KE, Hunt CH, Flores VH, *et al.* Evidence-based guideline: Neuromuscular ultrasound for the diagnosis of carpal tunnel syndrome. *Muscle Nerve* 2012;46:287-93.
5. Paliwal PR, Therimadasamy AK, Chan YC, Wilder-Smith EP. Does measuring the median nerve at the carpal tunnel outlet improve ultrasound CTS diagnosis? *J Neurol Sci* 2014;339:47-51.
6. Kaymak B, Özçakar L, Cetin A, Candan Cetin M, Akinci A, Haşcelik Z, *et al.* A comparison of the benefits of sonography and electrophysiologic measurements as predictors of symptom severity and functional status in patients with carpal tunnel syndrome. *Arch Phys Med Rehabil* 2008;89:743-8.
7. Kotevoglou N, Gülbahce-Saglam S. Ultrasound imaging in the diagnosis of carpal tunnel syndrome and its relevance to clinical evaluation. *Joint Bone Spine* 2005;72:142-5.
8. Mohammadi A, Afshar A, Etemadi A, Masoudi S, Baghizadeh A. Diagnostic value of cross-sectional area of median nerve in grading severity of carpal tunnel syndrome. *Arch Iran Med* 2010;13:516-21.
9. Kamolz LP, Beck H, Haslik W, Högl R, Rab M, Schrögenderer KF, *et al.* Carpal tunnel syndrome: A question of hand and wrist configurations? *J Hand Surg Br* 2004;29:321-4.
10. Moghtaderi A, Izadi S, Sharafadinzadeh N. An evaluation of gender, body mass index, wrist circumference and wrist ratio as independent risk factors for carpal tunnel syndrome. *Acta Neurol Scand* 2005;112:375-9.
11. Vögelin E, Mészáros T, Schöni F, Constantinescu MA. Sonographic wrist measurements and detection of anatomical features in carpal tunnel syndrome. *ScientificWorldJournal* 2014;2014:657906.
12. Claes F, Meulstee J, Claessen-Oude Luttikhuis TT, Huygen PL, Verhagen WI. Usefulness of additional measurements of the median nerve with ultrasonography. *Neurol Sci* 2010;31:721-5.
13. Bianchi S, Martinoli C. *Ultrasound of the Musculoskeletal System*. Berlin: Springer; 2007.
14. Kim MK, Jeon HJ, Park SH, Park DS, Nam HS. Value of ultrasonography in the diagnosis of carpal tunnel syndrome: Correlation with electrophysiological abnormalities and clinical severity. *J Korean Neurosurg Soc* 2014;55:78-82.
15. Klauser AS, Halpern EJ, De Zordo T, Feuchtner GM, Arora R, Gruber J, *et al.* Carpal tunnel syndrome assessment with US: Value of additional cross-sectional area measurements of the median nerve in patients versus healthy volunteers. *Radiology* 2009;250:171-7.
16. Fleiss J. *The Design and Analysis of Clinical Experiments*. New York: John Wiley and Sons; 1986.
17. Altinok T, Baysal O, Karakas HM, Sigirci A, Alkan A, Kayhan A, *et al.* Ultrasonographic assessment of mild and moderate idiopathic carpal tunnel syndrome. *Clin Radiol* 2004;59:916-25.
18. Bayrak IK, Bayrak AO, Tilki HE, Nural MS, Sunter T. Ultrasonography in carpal tunnel syndrome: Comparison with electrophysiological stage and motor unit number estimate. *Muscle Nerve* 2007;35:344-8.
19. Buchberger W, Judmaier W, Birbamer G, Lener M, Schmidauer C. Carpal tunnel syndrome: Diagnosis with high-resolution sonography. *AJR Am J Roentgenol* 1992;159:793-8.
20. Fowler JR, Munsch M, Tosti R, Hagberg WC, Imbriglia JE. Comparison of ultrasound and electrodiagnostic testing for diagnosis of carpal tunnel syndrome: Study using a validated clinical tool as the reference standard. *J Bone Joint Surg Am* 2014;96:e148.
21. Ghasemi-Esfé AR, Khalilzadeh O, Vaziri-Bozorg SM, Jajroudi M, Shakiba M, Mazloumi M, *et al.* Color and power Doppler US for diagnosing carpal tunnel syndrome and determining its severity: A quantitative image processing method. *Radiology* 2011;261:499-506.
22. Ghasemi-Esfé AR, Khalilzadeh O, Mazloumi M, Vaziri-Bozorg SM, Niri SG, Kahnouji H, *et al.* Combination of high-resolution and color Doppler ultrasound in diagnosis of carpal tunnel syndrome. *Acta Radiol* 2011;52:191-7.
23. Keleş I, Karagülle Kendi AT, Aydin G, Zöğ SG, Orkun S. Diagnostic precision of ultrasonography in patients with carpal tunnel syndrome. *Am J Phys Med Rehabil* 2005;84:443-50.
24. Kwon BC, Jung KI, Baek GH. Comparison of sonography and electrodiagnostic testing in the diagnosis of carpal tunnel syndrome. *J Hand Surg Am* 2008;33:65-71.
25. Lee CH, Kim TK, Yoon ES, Dhong ES. Correlation of high-resolution ultrasonographic findings with the clinical symptoms and electrodiagnostic data in carpal tunnel syndrome. *Ann Plast Surg* 2005;54:20-3.
26. Yesildag A, Kutluhan S, Sengul N, Koyuncuoglu HR, Oyar O, Guler K, *et al.* The role of ultrasonographic measurements of the median nerve in the diagnosis of carpal tunnel syndrome. *Clin Radiol* 2004;59:910-5.
27. Zhang L, Rehemutula A, Peng F, Yu C, Wang TB, Chen L, *et al.* Does the ratio of the carpal tunnel inlet and outlet cross-sectional areas in the median nerve reflect carpal tunnel syndrome severity? *Neural Regen Res* 2015;10:1172-6.
28. El Miedany Y, El Gaafary M, Youssef S, Ahmed I, Nasr A. Ultrasound assessment of the median nerve: A biomarker that can help in setting a treat to target approach tailored for carpal tunnel syndrome patients. *Springerplus* 2015;4:13.
29. Mohammadi A, Ghasemi-Rad M, Mladkova-Suchy N, Ansari S. Correlation between the severity of carpal tunnel syndrome and color Doppler sonography findings. *AJR Am J Roentgenol* 2012;198:W181-4.
30. Naranjo A, Ojeda S, Mendoza D, Francisco F, Quevedo JC, Erasquin C, *et al.* What is the diagnostic value of ultrasonography compared to physical evaluation in patients with idiopathic carpal tunnel syndrome? *Clin Exp Rheumatol* 2007;25:853-9.
31. Claes F, Kasius KM, Meulstee J, Verhagen WI. Comparing a new ultrasound approach with electrodiagnostic studies to confirm clinically defined carpal tunnel syndrome: A prospective, blinded study. *Am J Phys Med Rehabil* 2013;92:1005-11.
32. El Miedany YM, Aty SA, Ashour S. Ultrasonography versus nerve conduction study in patients with carpal tunnel syndrome: Substantive or complementary tests? *Rheumatology (Oxford)* 2004;43:887-95.
33. Wiesler ER, Chloros GD, Cartwright MS, Smith BP, Rushing J, Walker FO, *et al.* The use of diagnostic ultrasound in carpal tunnel syndrome. *J Hand Surg Am* 2006;31:726-32.
34. Kang S, Kwon HK, Kim KH, Yun HS. Ultrasonography of median nerve and electrophysiologic severity in carpal tunnel syndrome. *Ann Rehabil Med* 2012;36:72-9.
35. Sato J, Ishii Y, Noguchi H, Takeda M, Toyabe S. Sonographic appearance of the pronator quadratus muscle in healthy volunteers. *J Ultrasound Med* 2014;33:111-7.
36. Singh V. *Textbook of Anatomy Upper Limb and Thorax*. Vol. 1. New Delhi: Elsevier; 2014.
37. Briggs T, Miles J, Aston W. *Operative Orthopaedics: The Stanmore*

- Guide. Boca Raton, Florida: CRC Press, Francis and Taylor Group; 2009.
38. Fu T, Cao M, Liu F, Zhu J, Ye D, Feng X, *et al.* Carpal tunnel syndrome assessment with ultrasonography: Value of inlet-to-outlet median nerve area ratio in patients versus healthy volunteers. *PLoS One* 2015;10:e0116777.
39. Cho KH, Lee YH, Lee SM, Shahid MU, Suh KJ, Choi JH, *et al.* Sonography of bone and bone-related diseases of the extremities. *J Clin Ultrasound* 2004;32:511-21.
40. Wakefield RJ, Gibbon WW, Conaghan PG, O'Connor P, McGonagle D, Pease C, *et al.* The value of sonography in the detection of bone erosions in patients with rheumatoid arthritis: A comparison with conventional radiography. *Arthritis Rheum* 2000;43:2762-70.